

SYMPTOMATIC ARNOLD-CHIARI MALFORMATION AND CRANIAL NERVE DYSFUNCTION: A CASE STUDY OF APPLIED KINESIOLOGY CRANIAL EVALUATION AND TREATMENT

Scott Cuthbert, DC,^a and Charles Blum, DC^b

ABSTRACT

Objective: To present an overview of possible effects of Arnold-Chiari malformation (ACM) and to offer chiropractic approaches and theories for treatment of a patient with severe visual dysfunction complicated by ACM.

Clinical Features: A young woman had complex optic nerve neuritis exacerbated by an ACM type I of the brain.

Intervention and Outcome: Applied kinesiology chiropractic treatment was used for treatment of loss of vision and nystagmus. After treatment, the patient's ability to see, read, and perform smooth eye tracking showed improvement.

Conclusion: Further studies into applied kinesiology and cranial treatments for visual dysfunctions associated with ACM may be helpful to evaluate whether this single case study can be representative of a group of patients who might benefit from this care. (*J Manipulative Physiol Ther* 2005;28:289.e1-289.e6)

Key Indexing Terms: *Chiropractic; Vision; Arnold-Chiari Malformation Type I; Muscle Weakness*

Arnold-Chiari malformation type I (ACM) is a projection of the medulla and cerebellum that extends through the foramen magnum and into the cervical spinal canal. Presumably during fetal life, fixation of the lower spinal cord or its nerve roots may exert traction on the upper cervical cord and brain stem, causing the medulla and cerebellum to herniate through the foramen magnum.¹

The natural history of symptomatic adult ACM type I is variable. Patients with this condition may develop corticospinal and sensory deficits, together with cerebellar signs and lower cranial nerve palsies in various combinations. It is rare for an ACM not to cause symptoms until adulthood. Paul et al² presented a series of 71 patients in whom a diagnosis of type I ACM was confirmed at operation, and the progress of the patients after posterior fossa decompression was analyzed. The length of their symptomatic histories varied greatly. Pain was the most common symptom (69% of patients); other symptoms

included weakness (56%), numbness (52%), and unsteadiness (40%). The presenting physical signs consisted of a foramen magnum compression syndrome (22%), central cord syndrome (65%), or a cerebellar syndrome (11%).

Developmental defects are frequently present in these cases, such as anomalies in the skull bones, spinal column, spinal cord, and meninges. Causes of the herniation may be embryological or as a result of the excessive force of precipitate labor, the use of obstetrical pituitrin, a fall on the buttocks or feet, a forceful stretching of the head from the neck, a blow on the vertex, and any activity that would increase intrathecal pressure or pathologically traction the meninges or neural substance.^{1,3}

The secondary effects of ACM often involve cranial nerve dysfunction. Visual disturbances are a common finding in symptomatic ACM. In 1 study, oculographic examinations were conducted in 24 cases of ACM. Disorders in vertical eye movements with spontaneous vertical nystagmus were frequently observed together with disturbances in visual tracking. Although these anomalies are not specific, they differ from those usually observed in multiple sclerosis (MS), which is often a differential diagnosis in such cases. Differential diagnosis is therefore essential because symptomatic ACM can often lead to many misdiagnoses such as psychiatric disorders, MS, and myasthenia gravis.³

Although there might be concern regarding chiropractic treatment of patients with asymptomatic ACM, there is evidence to support the safety of this care. Murphy et al⁴

^a Private Practice of Chiropractic, Chiropractic Health Center, Pueblo, Colo.

^b Private Practice of Chiropractic, Santa Monica, Calif.

Sources of support: none

Submit requests for reprints to: Scott Cuthbert, DC, Chiropractic Health Center, 255 West Abriendo Avenue, Pueblo, CO 81004 (e-mail: cranialdc@hotmail.com).

Paper submitted April 15, 2003; in revised form June 6, 2003. 0161-4754/\$30.00

Copyright © 2005 by National University of Health Sciences. doi:10.1016/j.jmpt.2005.03.001

reported 2 case histories of patients with ACM who were treated with chiropractic adjustments to the cervical spine for conditions unrelated to their anomaly. The patients received adjustments to their cervical spine with no complications noted, and they concluded that asymptomatic type I ACM is not necessarily a contraindication for skilled adjustments to the cervical spine.

In another study by Smith,⁵ a patient had an array of diffuse symptoms. Because she had the ACM without overt neurological sequelae, the ACM was considered an incidental finding. The patient received adjustments to an occipitoatlantoaxial complex subluxation and noted an improvement of her symptoms. It was concluded that when surgery or medication is not of medical urgency for ACM, then a trial of upper cervical chiropractic care may be considered.

Chiropractic care of visual problems has been reported.⁶⁻⁹ Therefore, the treatment of the vision-related condition in the following case was not without rationale.

Differential diagnosis of this patient's visual problem was achieved using applied kinesiology's (AK) cranial and cranial nerve testing procedures, which are described briefly here.

Ocular lock is a testing procedure used in AK to attempt to discover 1 form of neurological disorganization within the nervous system. The theory is that it shows the failure of the eyes to work together on a binocular basis through the cardinal positions of gaze.¹⁰⁻¹⁴ This is usually not gross pathology of cranial nerves III, IV, and VI; rather it shows poor functional organization. When the eyes are moved in a specific direction, a previously strong indicator muscle will weaken. The eyes must work together as a team so that each eye is directed to the same fixation point on a page, somewhat like 2 spotlights highlighting a performer at the center of the stage (convergence). The focus of the eyes must also be quickly adjusted from one distance or angle to another (accommodation). The eyes must be able to track or scan along the horizon or a line of print smoothly and evenly so that the brain can receive a flow of sequentially correct visual information. Eye motion and position are integrated by proprioceptors throughout the body, as well as those of the vestibular apparatus and the head-on-neck reflexes. When a dysfunction of the eye muscles or cranial nerves III, IV, or VI exists, the ocular lock finding will be positive.

Challenge is another diagnostic procedure used in AK to determine the body's ability to cope with external stimuli that can be physical, chemical, or mental. After an external stimulus is applied, muscle testing procedures are performed to determine an improvement or weakening of the muscle strength as a result of the stimulus.^{10,11,15,16}

Measurable cranial bone movement ranges between 0.001 and 0.005 in (40 μm to 1.5 mm) according to different authorities. Forty micrometers may seem imperceptible to anyone looking to detect it, but researchers in the

cranial field have detected movements of as little as 1 μm . The amount of movement at the superior margins of the greater wings of the sphenoid where it meets the frontal bone may reach 40 μm .^{17,18}

In AK, the diagnostic method used to identify cranial faults is termed a cranial challenge. In Magoun's¹⁹ text on cranial treatment, *Osteopathy in the Cranial Field*, there are 5 different methods described for "securing the point of balanced membranous tension which must be followed to secure the best results." Magoun states:¹⁹

A. EXAGGERATION. This is the ordinary procedure for the usual case and is employed when not contraindicated...To employ this method, increase the abnormal relationship at the (cranial) joint by moving the articulation slightly in the direction towards which it was lesioned...To do this with the 2 members of an articulation augments the chance of securing a reduction because of the increased resilience of the membranes.

The AK rebound challenge procedure is based on Magoun's exaggeration procedure, the theory that the physician momentarily increases the fault pattern of a single bone or group of bones, with the intention that this vector of force placed into the skull will cause a temporary increase in the tension of the reciprocal tension membranes (RTMs) of the craniosacral system. It is supposed that if this vector of force increases the RTM tension, it will produce a momentary lowering of the overall muscle tone of an indicator muscle. If this vector decreases the RTM tension, it will produce an improvement in function in a muscle inhibited by the cranial fault. Correction is performed by sustaining pressure through several respiratory cycles (using the same vector as the challenge) and allows the RTM to accumulate enough energy or tension to free itself and spring back, or rebound, into the correct relationship. In cranial terminology, this is called the exaggeration correction.

Therapy localization (TL) is a diagnostic procedure in AK that consists of placing the patient's hand over areas of suspected involvement, then uses muscle testing procedures to determine change in strength. Placing the patient's hand on different locations stimulates sensory nerve endings. Muscle testing procedures are then employed to determine a change in muscle function after the TL has been applied. TL is combined with other diagnostic findings to arrive at a final conclusion.^{10,11,13,20,21}

The category system of analysis was developed by DeJarnette^{22,23} and modified by Goodheart.¹¹ This system organizes patterns of various possible bodily distortions, particularly the disturbances that occur in the sacroiliac and lumbosacral regions. Briefly, category I relates to imbalance or torque at the anterior aspect of the sacroiliac junction and its effect on meningeal balance and cerebrospinal fluid fluctuation. Category II is associated with various degrees of posterior sacroiliac joint ligamentous sprain and trauma. A category III condition occurs when the pelvis can no longer maintain weight-bearing capacity and shifts the burden to the lumbosacral junction with resultant discopathy and

radiculopathy. In theory, these pelvic distortions produce reciprocal distortions throughout the body, especially in the pectoral girdle and first rib heads, the temporomandibular joint (TMJ), the cervical spine, and the skull. It is hypothesized that many muscle groups are involved in the compensations a body makes to these pelvic category distortions.^{10,11,22-24} The following case report described a patient's response to AK treatment.

CASE REPORT

A 20-year-old female patient with retrobulbar neuritis (optic nerve neuritis) of the right eye, as diagnosed by her general practitioner, ophthalmologist, and a neuroradiologist, reported that she had "gone blind" in her right eye 11 days earlier and was markedly frightened. She stated that everyone's face had suddenly gone blank to her upon awakening one morning.

In relation to her visual problem, a radiologist's interpretation of a magnetic resonance imaging performed a week after the onset of her symptoms included ACM of the brain, with a 5-mm herniation of the cerebellar tonsils into the spinal canal. Her general medical physician and ophthalmologist had scheduled her for an MS evaluation.

Three months before her vision loss, the woman and her mother were involved in an automobile accident. Their car slid backward and down into a 15-ft ditch. No significant damage to the car or the passengers was perceived at the time, but the patient reported having her first migraine headache 3 days after the automobile accident. She had 2 disk injuries in the neck 3 years previously and had chiropractic reduction of the disk injury under anesthesia. A lumbar disk was also treated at the same time in this way.

At the patient's initial examination, she could only detect outlines of large objects and specific colors with her right eye. With her left eye covered, she could not detect the presence of the Snellen eye chart on the wall. She revealed an example of the ocular lock phenomenon, with saccadic motion in both eyes. Almost every angle of her gaze exhibited disorganization in the movement of the 2 eyes, or "see-saw nystagmus,"³ a common finding in ACM cases.

To determine if cranial treatment would be applicable to help resolve the cranial nerve problems found in this case, a therapeutic trial of correcting cranial faults was determined through the upper trapezius muscles, as well as an improvement in the organization of the eye muscles.

Manual muscle testing revealed consistent strength in the sternocleidomastoid, anterior scalene, and deep neck flexor muscles. Passive hyperflexion of the cervical spine produced exquisite pain in the upper cervical area. There was pain and weakness on testing the upper trapezius muscle bilaterally. Pincer palpation was positive to the rectus capitis posterior minor muscle, suggestive of a possible myofascial dural interaction.²⁵⁻²⁹ The cervical stretching test and foramina compression tests were positive for pain in the

suboccipital area. Cervical ranges of motion in flexion and rotation were painful and limited.

Evaluation of the right external pterygoid muscle elicited positive TL and challenge, and the muscle was sensitive to palpation. A category II pelvic subluxation on the contralateral side of the body was present. The interaction between the TMJ and the pelvis has been reported.³⁰

The patient had an internal and external frontal cranial bone subluxation on opposite sides (found by challenge), as well as a lateral sphenoid strain on the left. These faults were believed to be affecting the shape of the orbit and the tension upon the tissues between the greater and lesser wings of the sphenoid. It was thought that this imbalance in osseous, meningeal, and myofascial tissue could negatively affect the cranial nerves passing into the eye.

The patient showed imbalance while standing on 1 leg with her eyes closed. The patient's balance improved immediately after TL to the cervical spine.^{11,31}

The gluteus maximus muscles were bilaterally weak, and a low-force instrument correction of her atlas vertebrae strengthened both muscles. She also had an oculo-basic fault on the right that was corrected. The oculo-basic finding and correction in this case correlate with the relationship found between the sacrum and pelvis and the neck and head.^{32,33}

Brieg et al³⁴ state that the primary source of adverse mechanical spinal cord tension is "set up directly by virtue of its anchorage at its 2 extremities, namely, the brain and cauda equina." The oculo-basic correction should theoretically improve the dural tension upon the coccyx, while also integrating the visual-righting reflexes with the pelvic-righting reflexes. "Oculo" represents the visual-righting reflexes, and "basic" is the Logan Basic technique for sacral and spinal treatment.^{32,35}

After treatment, the patient showed balance when standing on 1 leg. Finger-to-finger testing had also been positive (right over left by 1 in), and after these treatments, she could accurately approximate her fingers with her eyes closed. After each cranial correction, eye movements were retested, and less saccadic motion and ocular confusion were noted. The cranial corrections were continued at the initial office visit until her eyes were moving through the cardinal fields of gaze smoothly and equally.

At the end of the first treatment, the patient noted that she could see the author's (S.C.) face through her right eye as well as her mother's face who was sitting approximately 10 ft across the room. She was then taken to a Snellen eye chart and was able to read 20/30 vision with her right eye.

On her second visit 2 days later, she had 20/20 visual acuity. There was still some reported blurriness with reading fine print, but she reported that every day since her first correction, she was seeing with greater clarity.

The AK reexamination indicated a change in her TMJ pattern with less deviation of the jaw with movement and less weakening of the indicator muscles during challenge and TL. The upper cervical subluxation remained corrected from the

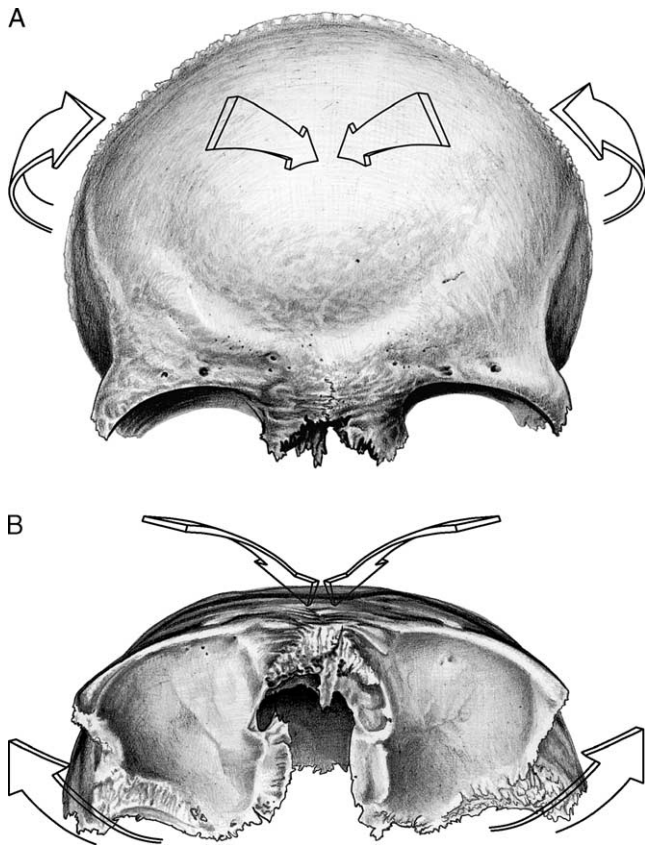


Fig 1. A, B, The frontal bone. Frontal cranial faults may affect the shape of the orbital cavity, the angulation of the orbital fissures, and the tension upon the nerves and vessels passing into and out of the eyes. Under these conditions, the cranial nerves may be subject to undesirable mechanical influences of various kinds including compression, stretch, angulation, torsion, edema, and many others. Reproduced with permission from Systems, DC, Pueblo, Colo.

first treatment. The upper trapezius muscles tested strong bilaterally. Extreme flexion of the head on the neck produced no pain. The same frontal bone malposition remained but did not produce dramatic weakening on challenge. The category II pelvic fault remained stable, and there was now only slight evidence of the ocular lock phenomenon.

The patient's vision continued to improve on follow-up visits. Her visual acuity reached 20/13 on her third visit, with no more blurriness to fine print. She was also reexamined by her ophthalmologist. His report noted, "Spontaneous improvement. No clinical or radiological evidence of MS. Patient saw a chiropractor...after manipulation, she saw better." The patient's vision remained normal during the 12-month period following initial treatment.

DISCUSSION

Cranial bone dysfunction and manipulative strategies are used within several chiropractic techniques, most com-

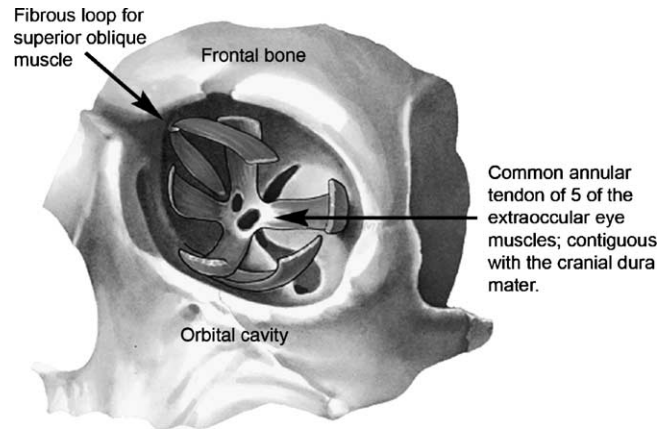


Fig 2. The sphenoid bone provides several important foramina for eye function. The optic canal through which cranial nerve II passes is vulnerable to disturbance when the sphenoid is shifted by the overlying frontal bone. The optic chiasm is created by the superior orbital fissure that lies between the greater and lesser wings of the sphenoid. Cranial nerves III, IV, and VI pass through this mobile opening, as well as the ophthalmic division of cranial nerve V, the frontal nerve, the lacrimal nerve, and the nasociliary nerves. Reproduced with permission from Systems, DC, Pueblo, Colo.

monly, AK and sacro-occipital technique.^{13,22,36-38} One theory of chiropractic philosophy and science is the concept of pressure on or interference with nerves which may decrease or facilitate nerve function.³⁹ Researchers have suggested that pressure on nerves within the cranium, and as they pass out of the cranium, may also alter nerve function. In 1987 Retzlaff and Mitchell¹⁷ compiled an annotated bibliography of more than 250 papers relating to cranial manipulative therapy. In 2000 Friedman et al¹⁸ listed more than 400 papers related to the cranial concept and more than 30 books describing this therapeutic modality alone.

With the cranial dysfunctions found and treated in this patient, in addition to the ACM already present in her cranium, the physical and visual defects cited in this case had a plausible origin. The optic nerves pass through the roots of the lesser wings of the sphenoid bone. With an internal frontal cranial fault or malposition on one side and an external frontal cranial fault or malposition on the other, as well as the lateral sphenoid strain present in her skull, an obliquity of the RTMs may result. The frontal bone curves inferiorly and anteriorly by the supraorbital ridges, which form the margin of the upper half of the orbital cavities. Frontal cranial faults may affect the shape of the orbital cavity, the angulation of the orbital fissures, and the tension upon the nerves and vessels passing into and out of the eyes. The anterior aspect of the falx on the internal aspect of the skull may be modified.^{17,18}

Disturbance to the sphenoid bone was suspected because of the findings during cranial challenge, TL, TMJ muscle testing, and palpation of the external pterygoid muscle. As a result of the external pterygoid muscle's attachment to the

pterygoid plate of the sphenoid, abnormal tension in the muscle might create subsequent tension upon the sphenoid bone sufficiently to affect the optic foramen and superior orbital fissure, thereby entrapping the optic, oculomotor, trochlear, the ophthalmic division of the trigeminal, and abducens nerves.⁴⁰ It is hypothesized that the tissue tensions between the superior and inferior orbital fissures between the greater and lesser wings of the sphenoid may be disturbed by these cranial faults. Frontal cranial faults may result in imbalance in 1 or both superior oblique muscles; therefore, ocular muscle deviation, or “ocular lock,” may occur as a result of the change in the length between the origin and insertion of the eye muscles or a disturbance in its passage through the fibrous loop attached to the frontal bone (Figs 1 and 2).

The anatomical relationship between the inner meningeal layers of the dura to the optic nerve is critical in cases such as these. The dural sleeve around the optic nerve (the dura, arachnoid, and pia mater all attach here) extends into the sclera of the eyeball and transmits tensions from the meninges to the nerves and muscles of the eyeball.^{13,40-43} The dural sleeve on the optic nerve contributes to the formation of the annular tendon, which is the origin for the extraocular muscles (Fig 2). Tension anywhere along the contiguous meninges may therefore be transmitted to the cranial nerves of the eye, the muscles of the eye, and to the eyeball itself. This is because the peripheral and the central nervous systems are a continuous tissue tract.

The ocular lock phenomenon is theorized to be a consequence of cranial faults. There have been findings that suggest the possible effects of dural tension upon the cranial nerves.^{13,17,18,41-46} The cranial nerves carry dural sleeves with them for some distance; therefore, abnormal meningeal tension may be transmitted to a nerve and affect its function.

Neuropathies that may result from cranial faults can be motor and/or sensory, and their severity depends on the amount of compression and neural irritation as well as the amount of ischemic radiculopathy. Brieg et al⁴⁷ have shown that problems result because of the entrapment neuropathy's effects on the vasculature of the nerve root. The effects of ischemia on cranial and peripheral nerve tissue have been studied, and increasing interest in the pathophysiology of nerve compression has indicated that a rise in intrafascicular pressure, as a result of edema, compression, or torsion of the nerve root, for example, can be damaging to neural tissue and function.^{44-46,48} Throughout the cranium, there are a number of sites where cranial nerves may be impinged upon by soft tissue at bony ridges or foraminal openings. These sites may reflect mechanical or physiological changes in neural function, leading to cranial peripheral neuropathy.⁴⁴⁻⁴⁶

Cranial nerves and other neural tissues in the skull are surrounded by connective tissue with viscoelastic properties similar to ligament and tendon, as well as arteries. The cranial neural tissue and intracranial connective tissue function as a continuum and are mechanically linked to

vital organs (eg, cerebrum, cerebellum, and cranial nerves) and pain-sensitive structures (eg, dura mater and cranial nerves), and injury or pathology can make the nervous tissue mechanosensitive. Dural sensitivity has been shown to be a significant contributor to head and neck pain.^{49,50}

CONCLUSION

In this case, cranial faults diagnosed through AK testing procedures appeared to resolve after treatment. It is difficult to discern whether the patient's condition would have resolved spontaneously. However, at the time of care, there seemed to be a relationship between the symptoms, relief, and the treatment rendered.

With this specific case, it was not determined whether her condition was secondary to occipital influences on the visual center or related to actual cranial nerve entrapment or myofascial dysfunction associated with the eye muscles. Further studies will need to be performed to evaluate similar patients with greater controls and concurrent neuroradiological studies to determine if the results of this study can be generalized to other patients with symptomatic ACM.

REFERENCES

1. Chusid JG. Correlative neuroanatomy & functional neurology. 19th ed. Los Altos (Calif): Lange Medical Publications; 1985. p. 335.
2. Paul KS, Lye RH, Strang FA, Dutton J. Arnold-Chiari malformation. Review of 71 cases. *J Neurosurg* 1983;58:183-7.
3. Brazis PW, Masdeu JC, Biller J. Localization in clinical neurology. 2nd ed. Boston: Little, Brown and Company; 1990. p. 175.
4. Murphy DR, Goldstein D, Katz M. Chiropractic adjustment to the cervical spine and the Arnold-Chiari malformation. *J Manipulative Physiol Ther* 1993;16:550-5.
5. Smith JL. Effects of upper cervical subluxation concomitant with a mild Arnold-Chiari malformation: a case study. *Chiropr Res J* 1997;4:77-81.
6. Carrick FR. Changes in brain function after manipulation of the cervical spine. *J Manipulative Physiol Ther* 1997;20:529-45.
7. Terrett A, Gorman R. The eye, the cervical spine, and spinal manipulative therapy: a review of the literature. *Chiropr Tech* 1995;7:43-54.
8. Gorman R. The treatment of presumptive optic nerve ischemia by spinal manipulation. *J Manipulative Physiol Ther* 1995;18:172-7.
9. Gorman R. Monocular visual loss after closed head trauma: immediate resolution associated with spinal manipulation. *J Manipulative Physiol Ther* 1995;18:308-14.
10. Walther DS. Applied kinesiology synopsis. 2nd ed. Pueblo (Colo): Systems DC; 2000.
11. Goodheart GJ. Applied kinesiology workshop procedure manual. Detroit (Mich): the author; 1964-1999.
12. Leisman G, Schwartz J. Ocular-motor function and information processing: implications for the reading process. *Int J Neurosci* 1977;8:7-15.
13. Walther DS. Applied kinesiology, vol. II: head, neck, and jaw pain and dysfunction—the stomatognathic system. Pueblo (Colo): Systems DC; 1983.

14. Crisera P. Cranio sacral energetics, vol. 1. Rome (Italy): the author; 1997. p. 217-8.
15. Klein R. A challenge based kinesiological protocol (or AK for DCs from Missouri), part one of a series. *Dig Chiropr Econ* 1988;30:40-3.
16. Klein R. Using the challenge based applied kinesiological protocol. *Dig Chiropr Econ* 1988;30:58-61.
17. Retzlaff EW, Mitchell FW. The cranium and its sutures. Berlin: Springer-Verlag; 1987. p. 68.
18. Friedman HD, Gilliar WG, Glassman JH. Osteopathic manipulative medicine approaches to the primary respiratory mechanism. San Francisco: International Manual Medicine Society; 2000. p. 221-53.
19. Magoun HL. Osteopathy in the cranial field. 3rd ed. Meridian (Iowa): Sutherland Cranial Teaching Foundation; 1976. p. 100.
20. Sprieser P. The therapy localization overload phenomena. *Digest Chiropr Econ* 1990;32:52-4.
21. Nicholas JA, Melvin M, Saraniti AJ. Neurophysiologic inhibition of strength following tactile stimulation of the skin. *Am J Sports Med* 1980;8:181-6.
22. DeJarnette MB. Cranial technique. Nebraska City (Neb): the author; 1979-1980.
23. DeJarnette MB. Sacro occipital technique. Nebraska City (Neb): the author; 1984.
24. Getzoff H. Sacro occipital technique categories: a systems method chiropractic technique. *Chiropr Tech* 1999;11:62-5.
25. Kenin S, Humphreys BK, Hubbard B, Cramer GD. Attachments from the spinal dura to the ligamentum nuchae: incidence, MRI appearance, and strength of attachment. *Proceedings of the 2000 International Conference of Spinal Manipulation*; 2000 Sept 21-24; Bloomington, MN; Des Moines (Iowa): Foundation for Chiropractic Education and Research; 2000. p. 202-4.
26. Hack GD, Koritzer RT, Robinson WL, Hallgren RC, Greenman PE. Anatomical relation between the rectus capitis posterior minor muscle and the dura mater. *Spine* 1995;20:2484-6.
27. Travell JG, Simons DG. Myofascial pain and dysfunction: the trigger point manual, vol I. Baltimore: Williams & Wilkins; 1992. p. 60-1.
28. Travell JG, Rinzler SH. The myofascial genesis of pain. *Postgrad Med* 1952;11:425-34.
29. Cuthbert SC. Applied kinesiology and myofascia. *Int J Appl Kinesiol Kinesiologic Med* 2002;34-9.
30. Lewit K. Chain reactions in disturbed function of the motor system. *Manual Med* 1987;3:27-9.
31. Ayres AJ. Sensory integration and praxis tests. Los Angeles (Calif): Western Psychological Services; 1989. p. 1-10.
32. Goodheart GJ. Applied kinesiology 1979 workshop procedure manual. Detroit (Mich): the author; 1979. p. 24-6.
33. Levy LM, DiChiro G, McCullough DC, Dwyer AJ, Johnson DL, Yang SS. Fixed spinal cord: diagnosis with MR imaging. *Radiol* 1988;169:773-8.
34. Brieg A. Adverse mechanical tension in the central nervous system. New York (NY): John Wiley & Sons; 1978. p. 39-40.
35. Coggins WN. Basic technique: a system of body mechanics. Creve Coeur (Mo): ELCO Publishing Company; 1983. p. 77-85.
36. Blum CL. The effect of movement, stress and mechanoelectric activity within the cranial matrix. *Int J Orthod* 1987;25:6-14.
37. Blum CL. Biodynamics of the cranium: a survey. *J Cranio-Mandib Pract* 1985;3:164-71.
38. Pederick FO. Developments in the cranial field. *Chiropr J Aust* 2000;30:13-23.
39. Leach RA. The chiropractic theories: principles and clinical applications. Baltimore (Md): Williams & Wilkins; 1994. p. 89-119.
40. Gray H. Anatomy of the human body. 29th ed. (American). Philadelphia: Lea & Feabgger; 1973. p. 1010-1.
41. Upledger JE. Craniosacral therapy II: beyond the dura. Seattle (Wash): Eastland Press; 1987. p. 115-30.
42. Blum C. Cranial therapeutic approach to cranial nerve entrapment part I: cranial nerves III, IV, and VI. *ACA J Chiropr* 1988;22:63-7.
43. Magoun H. Entrapment neuropathy in the cranium. *J Am Osteopath Assoc* 1968;67:779-87.
44. Patten J. Neurological differential diagnosis. 2nd ed. Berlin: Springer-Verlag; 1995. p. 245-6.
45. Moller AR. The cranial nerve vascular compression syndrome. *Rev Treat Acta Neurochir* 1991;113:18-23.
46. Dyck PJ, Thomos PK. Peripheral neuropathy, vol 2. 3rd ed. Philadelphia: WB Saunders; 1993. p. 513-67.
47. Brieg A, Tumbull I, Hassler O. Effects of mechanical stresses on the spinal cord in cervical spondylosis. A study of fresh cadaver material. *J Neurosurg* 1966;25:45-56.
48. Lundborg G. Intraneural microcirculation. *Orthop Clin North Am* 1988;19:1-12.
49. Butler DS. Mobilization of the nervous system. Melbourne: Churchill-Livingstone; 1991. p. 75-7.
50. Steiger HJ. The anatomy of headache. *Manual Med* 1987; 3:37-9.